

Incorrect orofacial functions until 5 years of age and their association with posterior crossbite

Maja Ovsenik

Ljubljana, Slovenia

Introduction: In addition to heredity, sucking habits, impaired nasal breathing, and atypical swallowing patterns are considered important factors in the etiology of posterior crossbite. The purpose of this study was to assess irregular orofacial functions to determine their correlation with posterior crossbite. **Methods:** Two hundred forty-three children were examined at the ages 3, 4, and 5. Irregular orofacial functions and morphologic traits of malocclusion were clinically evaluated. The prevalence of posterior crossbite and the relationship with incorrect orofacial functions was determined. Data were analyzed by using the chi-square test and repeated measures analysis of variance (ANOVA). **Results:** Posterior crossbite at 5 years of age was found in 20% of the children. Half of the crossbite children had dummy sucking or were bottle-fed. Bottle feeding decreased during the observation years, but atypical swallowing, thumb sucking, and mouth breathing persisted. Mouth breathing and dummy sucking behavior were found to be statistically significantly different between the crossbite and noncrossbite groups of children. Atypical swallowing patterns increased in children with crossbite and decreased in those without crossbite. The difference was statistically significantly different (repeated measures ANOVA, $P = 0.038$). **Conclusions:** Every clinical examination of children in the deciduous dentition with sucking habits should include assessment of orofacial functions, especially the swallowing pattern, which was found to be an important factor in the etiology for posterior crossbite development. (Am J Orthod Dentofacial Orthop 2009;136:375-81)

Posterior crossbite is defined as a transverse discrepancy in arch relationship in which the palatal cusps of at least one maxillary posterior tooth do not occlude in the central fossa of the opposing mandibular tooth.¹ This malocclusion can have a multifactorial origin, in which, in addition to heredity and food consistency, environmental factors such as sucking habits, mode of breathing, and swallowing pattern play fundamental roles.²⁻⁹

Posterior crossbite in the early stage of dental development can be either dental or functional. Dental crossbite is local asymmetry of the maxillary dental arch without midline shift. Functional crossbite, on the other hand, is characterized by symmetrical constriction of the maxillary arch, midline deviation, chin deviation, and facial asymmetry.¹⁰

In white children, the prevalence of posterior crossbite in the deciduous and mixed dentitions varies from 8% to 23%, with predominance of unilateral forms,¹

but, in rural parts of the world, such as Colombia, the reported prevalence is significantly lower—only 4.6%.¹¹ One explanation for the low rate in Colombian children might be that they are breast-fed for at least the first year of life, and sucking habits are rare. The differences between racial groups might be partly caused by cultural variations in the prevalence of sucking habits in these populations.¹²

Several authors have reported on the close relationship between sucking habits and the development of malocclusion.^{2,8,9} Furthermore, Ogaard et al¹³ reported on the difference in the prevalence of pacifier sucking habits between Swedish and Norwegian children and also found a higher prevalence of unilateral posterior crossbite among Swedish pacifier suckers, especially girls. Moreover, other studies have also pointed out that the use of pacifiers in small children has increased over the past decades, as has the tendency to prolong the habit.^{3,13-15}

Although a close relationship between form and function is recognized by many authors, the degree of interplay is still a matter of conjecture.^{16,17} The development of malocclusion must be considered as a result of interactions among the genetically determined developmental factors and several external and internal environmental factors, including orofacial function. Whereas a close relationship between irregular orofacial functions and unilateral functional crossbite was reported by

Assistant professor, Department of Orthodontics, Medical Faculty, University of Ljubljana, Ljubljana, Slovenia.

The author reports no commercial, proprietary, or financial interest in the products or companies described in this article.

Reprint requests to: Maja Ovsenik, University of Ljubljana, Medical Faculty, Department of Orthodontics, Vrazov trg 2, 1000 Ljubljana, Slovenia; e-mail, maja.ovsenik@dom.si.

Submitted, November 2007; revised and accepted, March 2008.
0889-5406/\$36.00

Copyright © 2009 by the American Association of Orthodontists.
doi:10.1016/j.ajodo.2008.03.018



Fig 1. Assessment of breathing mode (left 2 pictures) and swallowing pattern (right 3 pictures). Breathing apparatus used to measure airflow from the nasal cavity in an open-mouth posture or through the oral vestibule.

several authors in different countries, adequate understanding of the form and function relationship requires longitudinal studies on populations of various genetic and environmental backgrounds.^{2,4,7,10,16,18}

The high prevalence of sucking habits in Slovenian children in the early stages of dental development was recently reported in a follow-up study.⁹ Because there has been no report on posterior crossbite of Slovenian children in the deciduous dentition, the aim of this study was to investigate the prevalence of posterior crossbite in Slovenian preschoolers at 5 years of age and its relationship to sucking habits, mouth breathing, and atypical swallowing patterns at ages 3, 4, and 5 years.

MATERIAL AND METHODS

The subjects for this research at the Medical Health Centre "Dr Anton Drolc" in Maribor, Slovenia, included 243 children (119 boys, 124 girls), examined at the ages of 3, 4, and 5 years. Before the clinical examinations, the parents answered a questionnaire regarding the child's sucking habits such as finger, thumb, or dummy sucking and bottle feeding. Sucking habits, irregular orofacial functions, and morphologic malocclusion traits in the transverse plane were registered with the method described by Ovsenik et al.⁹

The modes of breathing and swallowing were registered during the clinical examinations.

The mode of breathing was determined independently by 3 investigators before the dental examination and further confirmed by questioning. The child was observed in a relaxed position, and it was noted whether he or she had competent lip closure. If this was not the case, the child's mode of breathing was determined with a special airflow registration device that registers the

difference in temperature of the airflow through the mouth or through the nose in an incompetent lip seal, thus distinguishing mouth breathing from incompetent lip seal. With the subject's mouth open, the breathing detector is placed in front of the mouth (distance, 1 cm), and the light sign or the beep signal on the airflow registration device confirms airflow through the mouth, thus determining improper breathing function (Fig 1, left 2 pictures).

The swallowing pattern was assessed by a method suggested by Melsen et al¹⁶ and modified so that tongue-thrust and teeth-apart swallowing were registered as one functional malocclusion trait category. The swallowing pattern was assessed while the child was swallowing saliva or small amounts of water. First, the mandibular movements and the perioral muscle contractions were observed during swallowing. Then the examiner palpated the temporalis and masseter muscles while the patient produced an unconscious swallow because this might deviate from a swallow on command. A normal swallowing pattern is characterized by tooth contact and activity of the masseter muscle, with little if any use of the perioral muscles. If a muscle contraction was not registered, an atypical swallowing pattern was noted. Each swallowing assessment was repeated 3 times, and the consensus opinion was accepted (Fig 1, right 3 pictures).

During the intraoral examination, posterior crossbite, midline deviation, and transverse buccal segment relationships were recorded, and alginate impressions of the maxillary and mandibular arches and wax bite registrations were obtained for all children. All study casts were assessed by the author.

A posterior crossbite was diagnosed when 2 or more pairs of teeth were involved in an occlusal anomaly with the buccal cusps of the maxillary posterior teeth

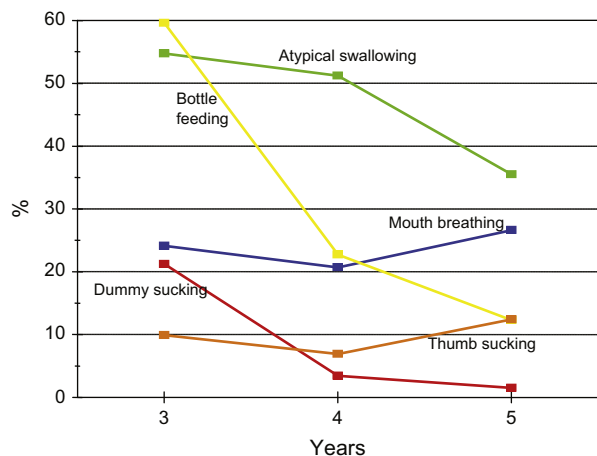


Fig 2. Distribution of sucking habits and irregular orofacial functions in Slovenian children without crossbite from ages 3 to 5 years.

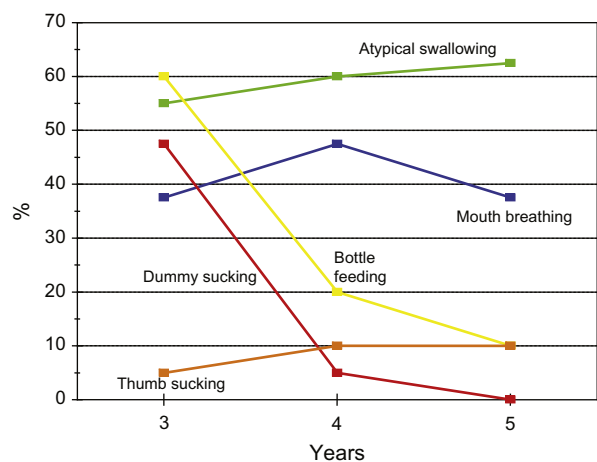
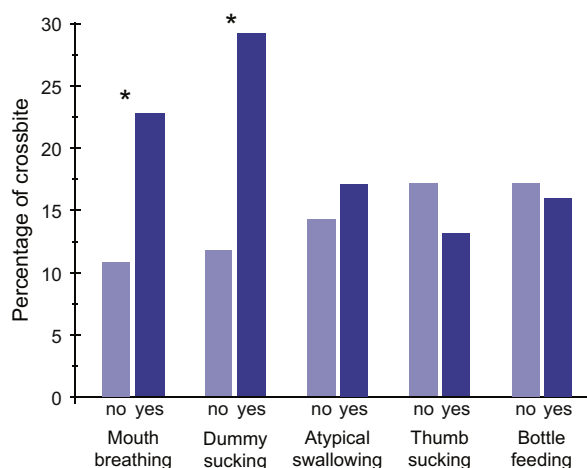


Fig 3. Distribution of sucking habits and irregular orofacial functions in children with unilateral crossbite from 3 to 5 years of age.

occluded lingually to those of the mandibular teeth with midline deviation.

Statistical analysis

Data were analyzed by using the chi-square test and repeated measures analysis of variance (ANOVA). The chi-square test was used to determine whether there were differences in the prevalence of crossbite in children with a particular irregular orofacial function. Repeated measures ANOVA was used to evaluate time evolution of irregular orofacial function problems in the 2 groups with the Wilks lambda multivariate test for assessment of statistical significance.



* Statistically significant difference $p < 0.05$ (χ^2 test)

Fig 4. Percentages of children with irregular orofacial functions between the crossbite group (right bars) and the noncrossbite group (left bars).

For the analysis, SPSS for Windows software (version 15, (SPSS, Chicago, Ill) was used. The level of significance was set at 0.05.

RESULTS

For the total sample, posterior crossbite at 5 years of age was diagnosed in 37 children (15.2%), with unilateral posterior crossbite in 34 (14.0%), and bilateral crossbite in 3 (1.2%). Posterior crossbite was diagnosed more frequently in girls ($n = 24, 19.4\%$) than in boys ($n = 16, 13.4\%$). The difference was not statistically significant.

The distribution of sucking habits and irregular orofacial functions is shown in Figure 2. Nearly 20% of children at the age of 3 years had dummy sucking, and, at the age of 4, it still remained in 5% of the children, but had almost disappeared toward the end of the deciduous dentition. Although dummy sucking and bottle feeding vanished almost completely at 5 years of age, thumb sucking persisted in all children from the ages of 3 to 5 years. Atypical swallowing pattern showed a tendency to decrease from 3 (55%) to 5 years (35%) of age, whereas mouth breathing was constant between 3 and 5 years.

The distribution of sucking habits and irregular orofacial functions in children with unilateral crossbite is shown in Figure 3.

Dummy sucking and bottle feeding decreased during the observation years, but atypical swallowing, thumb sucking, and mouth breathing persisted.

The difference of irregular orofacial functions between the crossbite and noncrossbite groups of children

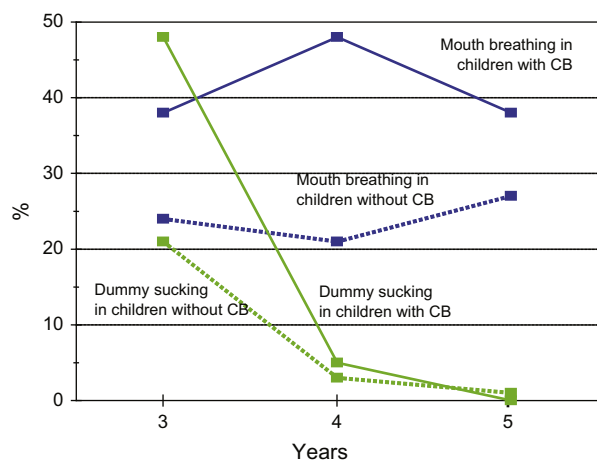


Fig 5. Percentages of children with sucking habits and irregular orofacial functions in the crossbite (CB) and noncrossbite (NCB) groups.

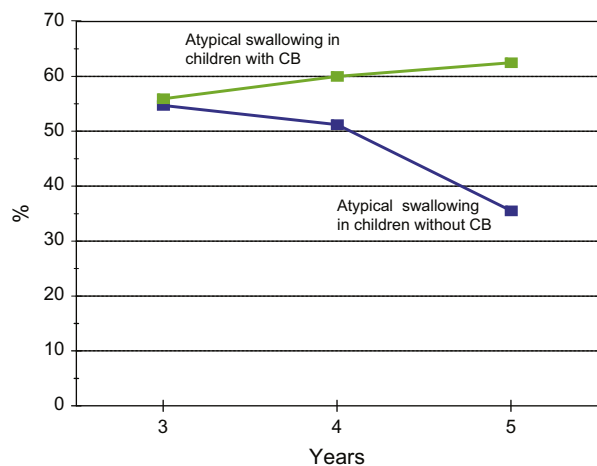


Fig 6. Percentages of children with atypical swallowing pattern: comparison between the crossbite (CB) and noncrossbite (NCB) groups.

is given in Figure 4. Mouth breathing and dummy sucking were statistically significantly different between the 2 groups. Therefore, a detailed view of these significant functional malocclusion traits is presented in Figure 5.

The percentages of children with dummy sucking and mouth breathing in the crossbite and noncrossbite groups is shown in Figure 5. At 3 years of age, almost 50% of the children with crossbite had dummy sucking, and but only 20% of the noncrossbite children had it.

Mouth breathing was nearly constant in both groups of children, although it was diagnosed in approximately 40% of the children with crossbite and in only 25% of those without it.

Table. Association of atypical swallowing pattern in children with and without crossbite

Effect	Value*	F	Hypothesis df	Error df	Significance (P)
Age	0.992	0.969	2	240	0.381
Age * crossbite	0.973	3.305	2	240	0.038

*Wilks' Lambda multivariate test.

As can be seen from Figures 2 and 3, atypical swallowing patterns were higher in the crossbite group and lower in the noncrossbite group.

The prevalence of atypical swallowing patterns in children with and without crossbite is presented in Figure 6. Atypical swallowing at 3 years of age was present in almost the same percentage of children regardless of malocclusion (noncrossbite and crossbite groups, Figs 2 and 3). The atypical swallowing pattern in the crossbite group showed a tendency to increase from the ages 3 to 5 years, whereas in the noncrossbite group it decreased substantially. The overall prevalence of atypical swallowing pattern (regardless of crossbite) did not change over time. The difference in time trends between children with and without crossbite was statistically significant (repeated measures ANOVA, Wilks lambda multivariate test, $P = 0.038$, Table).

The significant effect of age * crossbite combination means that the time evolution of atypical swallowing is different with respect to crossbite, but the average prevalence does not differ.

DISCUSSION

Posterior crossbite has been reported to be a prevalent malocclusion of the deciduous dentition in white children and, if left untreated, can lead to craniofacial asymmetry and temporomandibular disorders.¹⁹ The main causative factor for posterior crossbite development is, in addition to heredity, reduction in the width of the maxillary arch compared with the mandibular arch as a result of sucking habits, mouth breathing due to enlarged tonsils, and adenoids.^{2,4,5,8,13,20-23}

The prevalence of posterior crossbite in this study was almost the same as found previously by several Scandinavian authors.^{2,4,13,18} The frequency of sucking habits in this longitudinal study was similar to results reported previously, although those studies were cross-sectional and concentrated mostly on the effects of prolonged sucking habits, indicating that irreversible malocclusions were produced if the sucking habit persisted beyond 4 years of age.⁷

The influence of sucking habits on the developing occlusion could be explained also, according to Melsen et al,⁸ by interference in the development of a normal

swallowing pattern because of the use of a dummy. Moreover, Ovsenik et al⁹ reported that sucking behavior (finger or dummy sucking and bottle-feeding) until 5 years of age was significant for an atypical swallowing pattern at the ages 6 to 9 years; this was also significant for a morphologic malocclusion severity score at age 12. In addition, the results from both studies reported that children with sucking habits have significantly more morphologic traits of malocclusion and therefore higher malocclusion severity scores.^{8,9} The most commonly occurring malocclusion traits in children with sucking habits were open bite, crossbite, and large overjet.^{1,9}

The swallowing pattern matures from infantile to somatic type in most children from the ages of 2 to 4 years. Several factors can account for persistence of an atypical swallowing pattern. Graber et al²⁴ reported that finger or dummy sucking, bottle feeding, mouth breathing, and tongue sucking can all contribute to cause the swallowing pattern to mature more slowly. Furthermore, nonnutritive sucking habits are reported to be the reason for the retained visceral or atypical swallowing pattern, described by forward tongue posture and tongue thrusting during swallowing, contraction of the perioral muscles, excessive buccinator hyperactivity, and swallowing without tooth contact.²⁴ The most alarming finding of this study was that 60% of the children at the age of 3 years were still bottle-fed; this equals the percentage of children with an atypical swallowing pattern (Fig 3).

An atypical swallowing pattern at 3 years of age was present in 55% of the children regardless of malocclusion, whereas, at 4 years of age, atypical swallowing patterns in the crossbite group tended to increase, but it changed dramatically in the noncrossbite group (Fig 6). The atypical swallowing pattern in the study by Ovsenik et al⁹ was present in half of the examined children at 3 years of age and changed significantly after 6 years, but was still present in 25% at 12 years of age; this agreed with both studies by Melsen et al^{8,16} in Danish and Italian children.

Proffit²⁵ believes that the role of atypical swallowing in the etiology of malocclusion is overestimated, although Melsen et al⁸ established that previous sucking habits had no significant influence on the type of swallowing, but children with sucking habits have significantly more distal and mesial occlusion and crossbite.

With regard to tongue-thrust swallowing, according to Melsen et al,¹⁶ simple and complex tongue-thrust swallowing patterns have different associations in the development of occlusion. Simple tongue thrusting is related to sagittal discrepancies, such as distal occlu-

sion, anterior overjet, open bite, and crossbite as well as crowding in the maxilla. In simple swallowing, the tongue might be in a high position, favoring spacing in the maxilla and maxillary overjet. In complex swallowing, low tongue position favors spacing in the mandible and mandibular overjet.

One explanation for the changed equilibrium in the oral cavity could be that, in children with dummy sucking habits, the tongue must take a lower position in the anterior part of the mouth floor. Because of incorrect tongue posture in the mouth, the dynamic balance between the influence of the tongue and that of the cheeks and lips is ruined; this can cause harmful consequences in the development of both jaws. There is no formative influence on the oral surfaces of the teeth and alveolar ridges for the maxilla anymore, and thus the activities of lips and cheeks on the buccal surfaces of the maxillary teeth and the alveolar ridge prevail. A consequence of a permanent loss of normal functional balance is a narrow and short maxilla. Diminished space in the maxilla forces the tongue to lie on the bottom of the oral cavity; this has a harmful influence on the growth and development of the jaws and dentition. This could, however, be an expression of functional adaptation to differences in form and function balance.

Moreover, the hypothesis about the relationship between dummy sucking and crossbite by Larsson³ explained that the dummy has become a natural part of the oral environment and stays in the child's mouth most of the time during the day and often also at night. It is often not sucked, but simply stays in the mouth passively. The lack of palatal support from the tongue results in a narrower maxillary arch. Because of the increased activity of the cheeks and, as the tongue exerts more lateral pressure on the mandibular canines and first molars, the dynamic balance between the influence of the tongue and that of the cheeks is ruined, resulting in a broader mandibular arch. These changes in equilibrium contribute to transversal disharmony and increase the risk of developing posterior crossbite.

In relation to previous studies, these results confirm that sucking habits have a direct influence on the developing occlusion and an indirect one in changing the swallowing pattern and are therefore considered a major factor in the etiology of posterior crossbite development.^{8,9,18}

So, the morphology of the dentition was not only significantly changed in children with posterior crossbite from the bad sucking habits, but also the functional analysis clinically diagnosed and expressed by the atypical swallowing pattern. According to Proffit,²⁵ the pressure on teeth should last at least for 6 hours a day to produce tooth movement. Since an atypical swallowing pattern does not exert pressure on the

dentition for 6 hours a day, the tongue posture on the mouth floor could be an etiological risk factor for cross-bite development.

Assessment of tongue posture and function is an important part of functional diagnosis in orthodontics. In addition to clinical examination, many methods for assessment of tongue posture and function have been developed and used recently but, for many reasons, did not prove to be suitable for observation of the tongue muscle in everyday clinical practice.²⁶ A clinical examination does not give an objective evaluation of tongue posture and function because of anatomic limitations, but, fortunately, well-trained orthodontists can clinically evaluate the difference in tongue movements between mature and tongue-thrust swallows.

Therefore, the important step of functional assessment in the standard clinical examination of growing children should be based on the assessment of tongue function (swallowing pattern), which was found to be significant for children with posterior crossbite.

According to these results, tongue function and posture should be further clinically evaluated when screening children for orthodontic treatment, especially in those with posterior crossbite. In preventive orthodontic treatment planning and screening of children for orthodontic treatment, the clinical examination should be based on the assessment of incorrect orofacial functions, especially tongue posture and function, which are caused mainly by bad sucking and feeding habits in the early period of the dental development. Further studies should evaluate more objectively tongue posture and function in children with posterior crossbite with ultrasonography, which has been found to be a noninvasive, accurate, and reliable method to assess swallowing pattern and tongue posture.²⁶

CONCLUSIONS

On the basis of these results, the following conclusions can be drawn.

1. To intercept the development of crossbites and functional shifts, the developing occlusion should be observed in the deciduous dentition period in children with prolonged sucking habits from 2 to 3 years. Not only should the morphology of the dentition be objectively evaluated, particularly the transverse occlusal relationship, but also any irregular orofacial functions, especially tongue function (swallowing pattern) and posture should be noted, since sucking habits have a direct effect on the developing occlusion and an indirect effect by changing the swallowing pattern.

2. Every clinical examination in children with sucking habits should include assessment of orofacial functions, especially the swallowing pattern, which was found to be an important factor in the etiology of posterior crossbite development. This assessment is important in functional diagnostic procedures in screening children for early orthodontic treatment.

The author thanks Franc Farčnik, Majda Korpar, Krista Sever-Cimerman, and Rastko Zorec for their contributions to this study.

REFERENCES

1. Cozza P, Baccetti T, Franchi L, Mucedero M, Polimeni A. Sucking habits and facial hyperdivergency as risk factors for anterior open bite in the mixed dentition. *Am J Orthod Dentofacial Orthop* 2005;128:517-9.
2. Bishara SE, Warren JJ, Broffitt B, Levy SM. Changes in the prevalence of nonnutritive sucking patterns in the first 8 years of life. *Am J Orthod Dentofacial Orthop* 2006;130:31-6.
3. Larsson E. The effect of dummy-sucking on the occlusion: a review. *Eur J Orthod* 1986;8:127-30.
4. Larsson E. Sucking, chewing, and feeding habits and the development of crossbite: a longitudinal study of girls from birth to 3 years of age. *Angle Orthod* 2001;71:116-9.
5. Larsson E, Ogaard B, Lindsten R. Rearing of Swedish, Norwegian, and Norwegian Sami children. *Scand J Dent Res* 1993;101:382-5.
6. Ovsenik M, Farcnik FM, Verdenik I. Comparison of intra-oral and study cast measurements in the assessment of malocclusion. *Eur J Orthod* 2004;26:273-7.
7. Lindsten R, Larsson E, Ogaard B. Dummy-sucking behaviour in 3-year old Norwegian and Swedish children. *Eur J Orthod* 1996;18:205-9.
8. Melsen B, Stensgaard K, Pedersen J. Sucking habits and their influence on swallowing pattern and prevalence of malocclusion. *Eur J Orthod* 1979;1:271-80.
9. Ovsenik M, Farcnik FM, Korpar M, Verdenik I. Follow-up study of functional and morphological malocclusion trait changes from 3 to 12 years of age. *Eur J Orthod* 2007;29:523-9.
10. Lindner A, Modeer T. Relation between sucking habits and dental characteristics in preschool children with unilateral cross-bite. *Scand J Dent Res* 1989;97:278-83.
11. Thilander B, Pena L, Infante C, Parada SS, de Mayorga C. Prevalence of malocclusion and orthodontic treatment need in children and adolescents in Bogota, Colombia. An epidemiological study related to different stages of dental development. *Eur J Orthod* 2001;23:153-67.
12. Malandris M, Mahoney EK. Aetiology, diagnosis and treatment of posterior cross-bites in the primary dentition. *Int J Paediatr Dent* 2004;14:155-66.
13. Ogaard B, Larsson E, Lindsten R. The effect of sucking habits, cohort, sex, intercanine arch widths, and breast or bottle feeding on posterior crossbite in Norwegian and Swedish 3-year-old children. *Am J Orthod Dentofacial Orthop* 1994;106:161-6.
14. Allen D, Rebellato J, Sheats R, Ceron AM. Skeletal and dental contributions to posterior crossbites. *Angle Orthod* 2003;73:515-24.
15. Warren JJ, Bishara SE. Duration of nutritive and nonnutritive sucking behaviors and their effects on the dental arches in the

- primary dentition. *Am J Orthod Dentofacial Orthop* 2002;121:347-56.
16. Melsen B, Attina L, Santuari M, Attina A. Relationships between swallowing pattern, mode of respiration, and development of malocclusion. *Angle Orthod* 1987;57:113-20.
 17. Vig PS, Showfety KJ, Phillips C. Experimental manipulation of head posture. *Am J Orthod* 1980;77:258-68.
 18. Modeer T, Odenrick L, Lindner A. Sucking habits and their relation to posterior cross-bite in 4-year-old children. *Scand J Dent Res* 1982;90:323-8.
 19. Pirttiniemi P, Kantomaa T, Lahtela P. Relationship between craniofacial and condyle path asymmetry in unilateral cross-bite patients. *Eur J Orthod* 1990;12:408-13.
 20. Kerr WJ, McWilliam JS, Linder-Aronson S. Mandibular form and position related to changed mode of breathing—a five-year longitudinal study. *Angle Orthod* 1989;59:91-6.
 21. Bresolin D, Shapiro PA, Shapiro GG, Chapko MK, Dassel S. Mouth breathing in allergic children: its relationship to dentofacial development. *Am J Orthod* 1983;83:334-40.
 22. Hanson ML, Cohen MS. Effects of form and function on swallowing and the developing dentition. *Am J Orthod* 1973;64:63-82.
 23. Behlfelt K, Linder-Aronson S, McWilliam J, Neander P, Laage-Hellman J. Dentition in children with enlarged tonsils compared to control children. *Eur J Orthod* 1989;11:416-29.
 24. Graber TM, Rakosi T, Petrovic AG. *Dentofacial orthopedics with functional appliances*. St Louis: Mosby; 1997.
 25. Proffit WR. On the aetiology of malocclusion. The Northcroft lecture, 1985, presented to the British Society for the Study of Orthodontics, Oxford, April 18, 1985. *Br J Orthod* 1986;13:1-11.
 26. Peng CL, Jost-Brinkmann PG, Yoshida N, Miethke RR, Lin CT. Differential diagnosis between infantile and mature swallowing with ultrasonography. *Eur J Orthod* 2003;25:451-6.